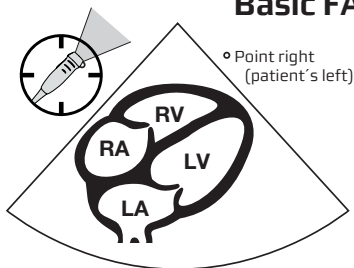


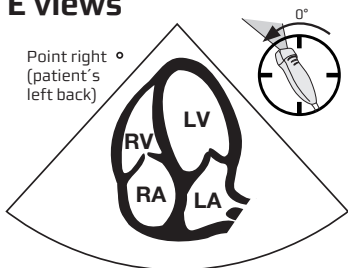
# Focus Assessed Transthoracic Echo (FATE)

Scanning through position 1-4 in the most favourable sequence

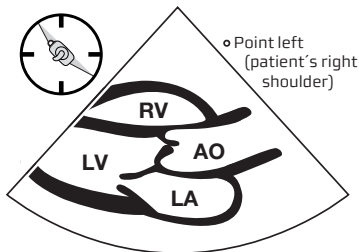
## Basic FATE views



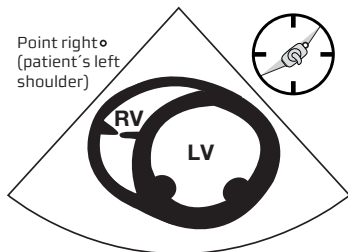
**Pos 1:** Subcostal 4-chamber



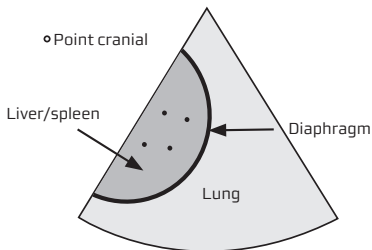
**Pos 2:** Apical 4-chamber



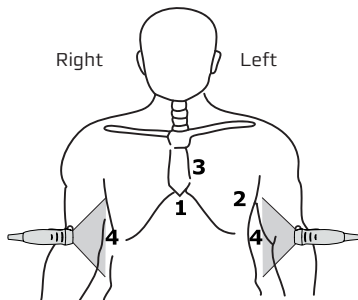
**Pos 3:** Parasternal long axis



**Pos 3:** Parasternal LV short axis



**Pos 4:** Pleural scanning



# Focus Assessed Transthoracic Echo (FATE)

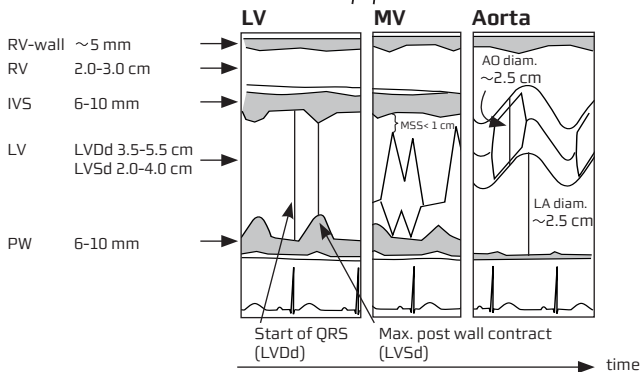
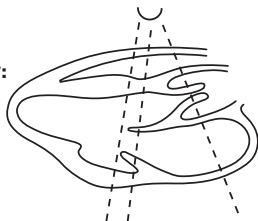
(European Journal of Anaesthesiology 2004; 21: 700-707)

1. Look for obvious pathology
2. Assess wall thickness + chamber dimensions
3. Assess bi-ventricular function
4. Image pleura on both sides
5. Relate the information to the clinical context
6. Apply additional ultrasound

## Dimensions and contractility:

$$FS = \frac{LVdD - LVsD}{LVdD}$$

$$EF \sim 2 \times FS$$



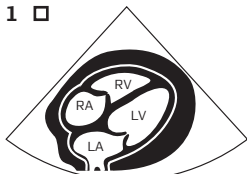
The global function of the heart is determined by the interaction between:

Right ventricle		Left Ventricle	
Systole:	Diastole:	Systole:	Diastole:
Preload	Compliance	Preload	Compliance
Afterload	Relaxation	Afterload	Relaxation
Contractility	Heart rate	Contractility	Heart rate
Heart rate		Heart rate	

Hemodynamic instability, perform a systematic evaluation of these determinants plus concomitant pathology: (e.g. pericardial effusion, pulmonary embolus, pleural effusion, pneumothorax, valvulopathy, dissection, defects)

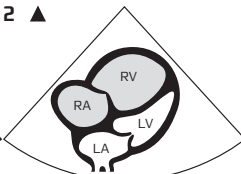
# Important pathology

1 □



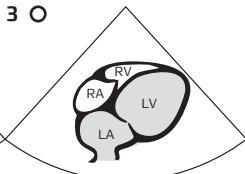
Pos 1: Pericardial effusion

2 ▲



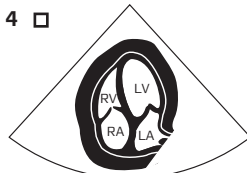
Pos 1: Dilated RA+RV

3 ○



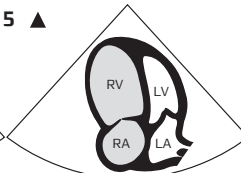
Pos 1: Dilated LA+LV

4 □



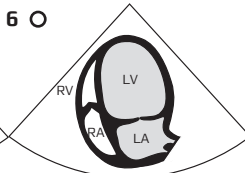
Pos 2: Pericardial effusion

5 ▲



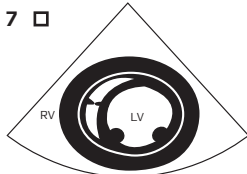
Pos 2: Dilated RA+RV

6 ○



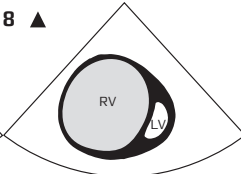
Pos 2: Dilated LA+LV

7 □



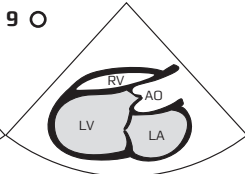
Pos 3: Pericardial effusion

8 ▲



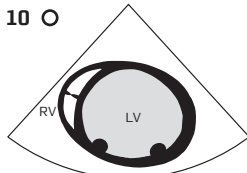
Pos 3: Dilated RV

9 ○



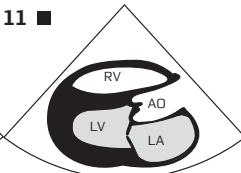
Pos 3: Dilated LV+LA

10 ○



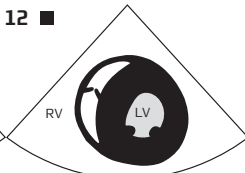
Pos 3: Dilated LV

11 ■



Pos 3: Hypertrophy LV+Dilated LA

12 ■

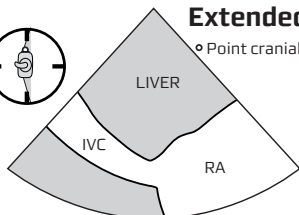


Pos 3: Hypertrophy LV

**PATHOLOGY TO BE CONSIDERED IN PARTICULAR:**

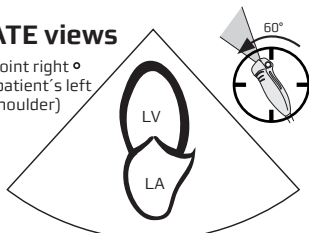
- Post OP cardiac surgery, following cardiac catheterisation, trauma, renal failure, infection.
- ▲ Pulmonary embolus, RV infarction, pulmonary hypertension, volume overload.
- Ischemic heart disease, dilated cardiomyopathy, sepsis, volume overload, aorta insufficiency.
- Aorta stenosis, arterial hypertension, LV outflow tract obstruction, hypertrophic cardiomyopathy, myocardial deposit diseases.

## Extended FATE views

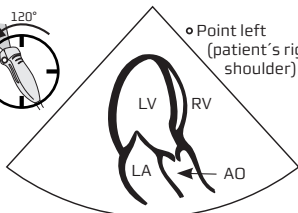
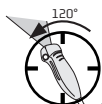

**Pos 1: Subcostal Vena Cava**

Point right ◦  
(patient's left shoulder)

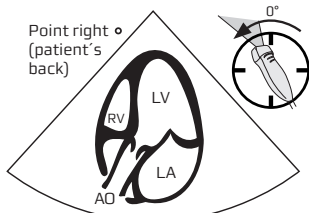


**Pos 2: Apical 2 - Chamber**

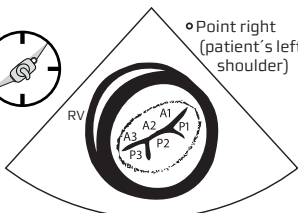


**Pos 2: Apical Long - axis**

Point right ◦  
(patient's back)

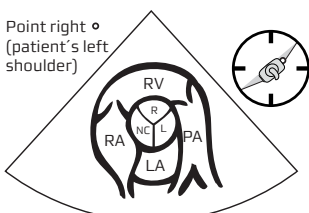


**Pos 2: Apical 5 - Chamber**



**Pos 3: Parasternal short axis mitral plane**

Point right ◦  
(patient's left shoulder)



**Pos 3: Parasternal aorta short axis**

CW: Peak pressure:  $V^2 \times 4$ ; AO < 2 m/s; PA < 1 m/s; T1 < 2.5 m/s

PW: Mitral Inflow desc. time 140 - 240 ms; MAX E < 1.2 m/s; E/A > 1 (Age dependent)

TVI: E/e' < 8-10; IVC < 20 mm; 50% collaps during inspiration is normal

### Systolic Ventricular Function

Ventricle	M-Mode	Normal	Mild ↓	Moderately ↓	Severely ↓
LV Pos 3, PS long	EF (%)	≥ 55	45 - 54	30 - 44	< 30
LV Pos 3, PS long	FS (%)	≥ 25	20 - 24	15 - 19	< 15
LV Pos 3, PS long	MSS (mm)	< 10	7 - 12	13 - 24	> 24
LV Pos 2, AP 4ch	Mapse (mm)	≥ 11	9 - 10	6 - 8	< 6
RV Pos 2, AP 4ch	Tapse (mm)	16 - 20	11 - 15	6 - 10	< 6

Right and left ventricle Eye Balling use all views



GE Healthcare

For additional information: [www.usabcd.org](http://www.usabcd.org)